

AQ: 1

# The Use of a Dynamic Elastomeric Fabric Orthosis to Manage Painful Shoulder Subluxation: A Case Study

AQ: 2 Martin J. Matthews, MPhil, Carol Payne, Martin Watson, PhD

## ABSTRACT

Across a variety of patient groups, the painful subluxed shoulder is a notoriously difficult clinical problem to manage. A number of treatment strategies have been proposed, which generally have mixed success. Dynamic Elastomeric Fabric Orthoses (DEFOs) represent an emerging treatment strategy for movement and postural control problems. Their use in the management of the painful subluxed shoulder has not, however, been previously documented. The case report provides a brief account of a young man with a painful subluxed shoulder as a result of a manual handling injury. At the end of an initial period of conservative management, the clinical problem had worsened, hindering the prospects for further active rehabilitation. A DEFO was prescribed for this client to provide physical support and facilitate physical activity. Full recovery (as judged by radiographic evidence) was achieved within a relatively short period of time after orthotic prescription. It is proposed that this intervention may be a useful adjunct to the management of this recurring clinical problem and that it warrants further investigation.

**KEY INDEXING TERMS:** shoulder subluxation, dynamic elastomeric fabric orthoses, rehabilitation

Allied health professionals use a variety of treatment options in the management of the painful subluxed shoulder, although this is a notoriously difficult clinical problem to treat. Musculoskeletal physical therapists have reported some success with the use of taping and strapping, in conjunction with manual techniques and exercise therapy.<sup>1</sup> Orthotists have had some success with the use of off-the-shelf neoprene orthoses for sports people with shoulder instability,<sup>2</sup> although these have a reputation for heat

retention and discomfort. Slings and arm supports have demonstrated some limited success in the treatment of the post-stroke hemiplegic subluxed shoulder,<sup>3</sup> although these have been more palliative in nature.

Dynamic elastomeric fabric orthoses (DEFOs) have been successfully used to improve form and/or function in a variety of patient groups, including children and adults with movement control problems<sup>4,5</sup> and adolescents with progressive skeletal changes.<sup>6</sup> The defining feature of all DEFOs is their custom-made snug-fitting elastomeric construction. They are worn next to the skin, being applied directly to the affected body part(s); i.e., shorts, leggings, vests, gloves, as appropriate. Their functional premise is that, by virtue of their tailored construction, they can exert a custom paratonic torsional, compressive, and supportive effect, thus positively influencing alignment, biomechanics, and neuromuscular activity specific to the individual and his/her affected body segments. Additional advantages include the facts that they are lightweight and relatively unobtrusive, are relatively easy to wear and don/doff, and can be easily used in conjunction with other interventions such as therapeutic exercise. This case study describes the use of a DEFO in the management of a subluxed painful shoulder after injury.

MARTIN J. MATTHEWS, MPhil, is affiliated with the School of Allied Health Professions, University of East Anglia, Norwich, United Kingdom.

CAROL PAYNE, is affiliated with the Norfolk and Norwich University Hospital NHS Foundation Trust, Norwich, United Kingdom.

MARTIN WATSON, PhD, is affiliated with the School of Allied Health Professions, University of East Anglia, Norwich, United Kingdom.

This research work was undertaken whilst the first author (M.J.M.) was registered as a postgraduate research student with the originating HEI under the supervision of one of the coauthors (M.J.W.). Since this work was undertaken, the first author has become an employee of the company that manufactured the orthoses referred to in the report.

AQ: 3

This article is a report of a routine clinical intervention, which, although somewhat innovative, is akin to that which typically occurs in this kind of scenario during everyday practice. The work did not in any way form part of a formal research project and thus ethical approval was not sought. The authors have confirmed that this is in keeping with local requirements for the submission of reports of case studies.

AQ: 4

This work was supported by the Norfolk and Norwich University Hospital NHS Foundation Trust.

Copyright © 2011 American Academy of Orthotists and Prosthetists.

Correspondence to: Martin J. Matthews, MPhil, School of Allied Health Professions, University of East Anglia, Norwich NR4 7TJ; e-mail: m.matthews@dmorthotics.com

AQ: 5

## CASE HISTORY

The subject was a 17-year-old male, who presented with a painful inferior glenohumeral joint subluxation after an injury sustained whilst pushing a heavy object. The precise mechanism of the injury was unknown. An initial radiograph was taken on the day of injury (April), during attendance at the accident and emergency department (Figure 1, left). No neurological deficits were identified and the client was referred for orthopedic review. In the interim, he was given a polysling to provide support, and advice was also given regarding rest and restorative exercise.

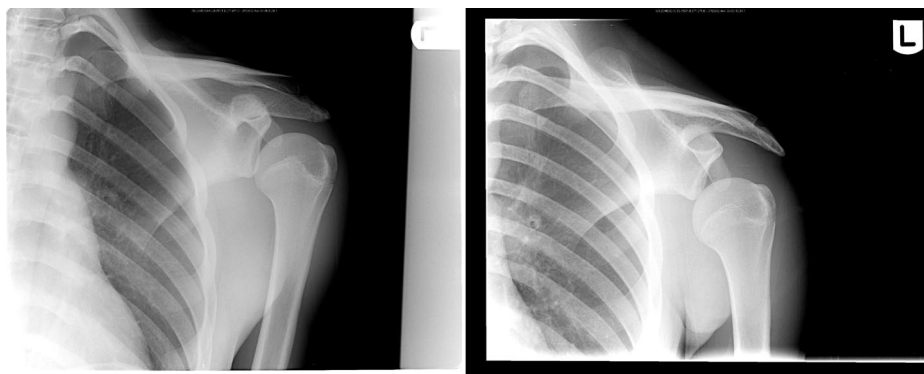

Figure 1. The x-rays at onset (left) and 4 months later (right).

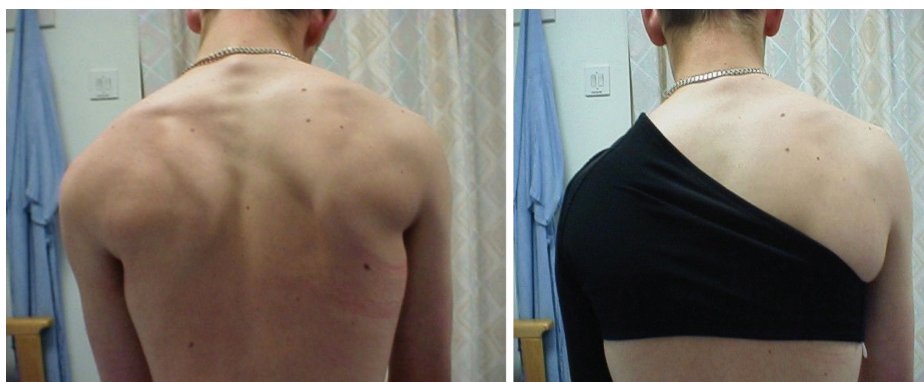

Figure 2. The client before first fit of the shoulder orthosis (left) and with the orthosis (right). Note the flattened scapula.

Radiography was repeated 4 months later (August) when the subject attended for orthopedic review (Figure 1, right). Examination revealed persisting inferior subluxation of the humeral head with no frank dislocation (A frank dislocation, otherwise known as a complete dislocation (luxation), is where the joints of both surfaces have lost contact with each other. When bones that make up the joint remain in partial contact it is called a subluxation or partial separation.), no bony injury, a positive sulcus sign with no ligamentous laxity and full range of passive movement.

The Polysling, which the subject had continued to wear, was unable to reduce pain. Posturally the client was unable to maintain an upright posture out of the sling without supporting the weight of his arm on his thigh. Muscle atrophy was now apparent, with global inhibition of the muscles of the left shoulder, shoulder girdle, and trunk (Figure 2, left). His left upper limb was grossly dysfunctional.

Physical therapy was immediately commenced to provide rehabilitation. Stretching exercises to maintain soft tissue range, and strengthening exercises to attempt to improve muscle balance around the shoulder, were provided. Shoulder stabilization remained an issue. After consultation with the principle orthotist, the immediate provision of a custom-made shoulder-stabilizing DEFO was identified as an additional therapeutic strategy. This aimed to provide upwardly acting force on the upper arm, encapsulating the body of biceps to provide the compressive purchase. Because of the

fabric's fixative properties, the sleeve was able to maintain position whilst at the same time providing an unloading effect on the humeral head, providing an upward movement of the upper arm through the close fit of the shoulder segment of the orthosis. The whole shoulder was encapsulated by an oblique section that passed from the shoulder down under the axilla of the opposing shoulder (Figure 2, right). The posterior section of the orthosis comprised a wide double reinforced section to apply a pressure to the scapula. The segment thinned to a wide band, which continued anteriorly under the axilla to terminate mid-chest. The anterior segment comprised a wide band with touch-and-close fastening. The long band could be pulled by the unaffected side, and thus applying the force to locate the subluxed shoulder, compress the scapula against the thoracic cage and also provide a retraction moment on the joint and shoulder complex. The anterior strap was held in place by the affected hand, allowing the nonaffected side to provide the corrective force culminating in a simple lay-over fastening. Wearer comfort was ensured by virtue of the circumferential compressive effect of the sleeve around the upper arm, which was able to reduce the shoulder dislocation without undue skin traction.

Donning occurred by sliding the arm segment up over the subluxed shoulder, pulling the strap segment together. This could be achieved independently by the subject. The client continued with therapy exercises postsupply.

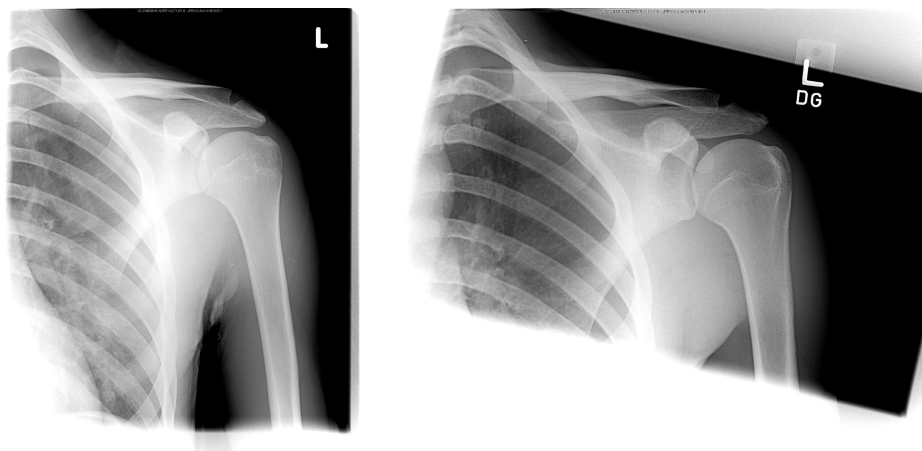


Figure 3. The x-ray in the shoulder stability orthosis (left) and at final attendance out of the orthosis 4 months later (right).

Radiographs taken 1 month after supply of the orthosis and commencement of physical therapy (September) indicated relocation of the humeral head whilst wearing the orthosis (Figure 3, left). Follow-up films 5 months later (March) suggested complete relocation, by which time the subject was no longer wearing the orthosis (Figure 3, right). Pain had apparently been relieved within a month of supply, and near-normal function restored by the time of the final x-ray.

## DISCUSSION

The subject described in this case report presented with a painful subluxed shoulder, sustained after a manual handling injury. This problem was initially managed conservatively, with imposed rest and immobilization using a sling. However, by 4 months, his condition had deteriorated, with increased subluxation and pain, combined with muscle wasting and functional disuse. Pain and dysfunctional biomechanics prevented successful exercise prescription, leading to a risk of further deterioration and symptom persistence. A novel orthotic intervention was therefore introduced. This seemed to provide relatively immediate support and functional facilitation, and improved compliance for physical therapy exercises. The third and fourth assessments showed progressive improvements in symptoms, marked also by objectively visible changes in x-ray evidence, such that the subject was eventually able to function without the orthosis and ultimately return to normal activity. Although it has been reported in previous literature<sup>7</sup> that such an orthotic effect would be difficult to achieve, in this instance a successful outcome seems nonetheless to be achieved. This could be due to the vertical force applied to the humerus, as against the diagonal pull provided by the sling reportedly used previously.

It is difficult to be definitive regarding the role played by this orthosis in the subject's progress, or regarding the

precise mechanism by which (if at all) this DEFO contributed to improvements in function. It seems fairly clear that, by 4 months after the initial injury, this subject had fallen into a downward spiral of painful disuse, atrophy, and altered joint biomechanics. (The extent to which this might have been preventable in the first instance, by more immediate positive management, remains a separate but important issue.) Corrective and restorative physical therapy exercises were therefore unachievable, leaving the patient at risk of further deterioration and chronicity. The prescription of an orthosis, which was supportive and corrective, whilst also permitting more normal joint activity (including restorative exercise) was probably instrumental in initiating the recovery process. Once such a tipping point had been established, it seems likely that muscle strengthening and (hence) intrinsic joint support through restored peri-articular muscle tone could begin to be achieved. Whether a similar positive outcome might have been reached by the use of other orthotic or therapeutic approaches is difficult to ascertain. However, the intervention described here seems to have played a positive role in this instance.

## CONCLUSION

The painful subluxed shoulder is notoriously difficult to manage. This case study describes an instance where a pragmatic approach to management was taken, via the prescription of a custom-made DEFO. It is proposed that this form of intervention warrants further evaluation and investigation.

## REFERENCES

1. Morrissey D. Proprioceptive shoulder taping. *J Bodywork Movement Ther* 2000;4:189–194.

2. Chu J, Kane E, Arnold B, et al. The effects of a neoprene shoulder stabiliser on active joint- reposition sense in subjects with stable or unstable shoulders. *J Athl Train* 2002;37:141–145.
3. Ada L, Foongchomcheay A, Canning C. Supportive devices for preventing and treating subluxation of the shoulder after stroke. *Cochrane Database* 2005;(1):CD003863.
4. Matthews M. A Pilot Study of Multiple Single Case Reports to Investigate the Effects of Dynamic Lycra Orthoses on Gait in Children with Diplegic Cerebral Palsy. Norwich, UK: School of Allied Health Professions, University of East Anglia; 2007.
5. Watson M, Crosby P, Matthews M. An evaluation of the effects of a dynamic Lycra orthosis on arm function in a late stage patient with acquired brain injury. *Brain Injury* 2007;21:753–761.
6. Matthews M, Crawford R. The use of dynamic Lycra orthosis in the treatment of scoliosis. A treatment case study. *Prosthet Orthot Int* 2006;30:174–181.
7. Cool J. Biomechanics of orthoses for the subluxed shoulder. *Prosthet Orthot Int* 1989;13:90–96.

## AUTHOR QUERIES

### AUTHOR PLEASE ANSWER ALL QUERIES

1

- 1—Please shorten the short title further as it exceeds 60 characters.
  - 2—Please provide educational degrees for the author “Carol Payne.”
  - 3—Please confirm whether the disclosure footnote is OK as set.
  - 4—Please confirm whether the footnote “This article...” is OK as given.
  - 5—Please confirm whether the corresponding author information is OK as set.
-